Scientific Papers. Series D. Animal Science. Vol. LXIX, No. 1, 2026
ISSN 2285-5750; ISSN CD-ROM 2285-5769; ISSN Online 2393-2260; ISSN-L 2285-5750

HISTOPATHOLOGICAL EVALUATION OF SELECTED TISSUES FROM WILD BOARS IN TRANSYLVANIA, ROMANIA

Adina Forina CIOATĂ (VIDREAN), Aurel DAMIAN, Oana Andreea PECE, Raluca MARICA, Melania Ioana CRIȘAN, Aurelia COROIAN

University of Agricultural Sciences and Veterinary Medicine of Cluj-Napoca, 3-5 Calea Mănăștur, 400372, Cluj-Napoca, Romania

Corresponding author email: aurelia.coroian@usamvcluj.ro

Abstract

The aim of this study was to evaluate histopathological changes in tissues from wild boars (Sus scrofa, L. 1758) from the Transylvania region, Romania. We collected tissue samples from lungs, heart, liver, kidneys and skeletal muscles from 5 wild boars. The samples were collected during post-mortem examinations. The samples were fixed in 10% buffered formalin, processed by paraffin embedding, sectioned at 2 µm, stained with hematoxylin and eosin and examined microscopically. Histopathological examination revealed severe parasitic and inflammatory lesions in the lungs, associated with cysts of Metastrongylus spp., Sarcocystis spp. in the myocardium, mild inflammatory lesions and occasional hepatic steatosis in the liver, as well as multifocal lymphohistiocytic interstitial nephritis in the kidneys. It should be noted that no histological changes were observed in skeletal muscle tissue. These observations provide essential information about the pathological state of wild boars in the studied region and emphasize the importance of histopathological monitoring for wildlife and meat quality assessment.

Key words*: histological analysis, organ lesions, wild boar.*

INTRODUCTION

The wild boar (*Sus scrofa,* L. 1758) is the most widespread species of wild and omnivorous mammal, in Europe, Asia and North Africa, which is part of the Suidae family and is the direct ancestor of the domestic pig. The wild boar is characterized by a high capacity to adapt to various environmental conditions and an opportunistic omnivorous diet. Due to its high mobility and variable feeding behavior, this wild species can be permanently exposed to numerous biological agents and environmental factors that can influence its health (Amici et al., 2012; Martin & Griswold, 2009). According to studies, game animals such as moose (*Alces alces*), roe deer (*Cervus elaphus*), roe deer (*Capreolus capreolus*), wild boar (*Sus scrofa*) and wild rabbit (*Lepus europaeus*) offer consumers opportunities to diversify their diet. (Rule et al., 2002; Falandysz et al., 2005). The use of wild species for monitoring environmental pollution is an essential tool, and according to the ethological characteristics of the wild boar, there is a probability of being exposed to heavy metal contamination (Martin & Griswold, 2009). Wild boar meat is an important source of protein with high biological value and is appreciated for its low fat content and favorable fatty acid profile compared to that of domestic animals (Quaresma et al., 2011; Kasprzyk et al., 2019). The consumption of wild boar meat has been steadily increasing, associated with consumer interests in organic products and extensive production systems (Kallas et al., 2021). Regarding wild animals, they can be frequently exposed to pathogens and parasites that can induce histopathological changes in internal organs. Infections with nematodes of the genus *Metastrongylus* are frequently found in wild boar and can cause bronchitis, bronchopneumonia and chronic pulmonary inflammatory reactions (García-González et al., 2013). Also, infections with protozoa of the genus *Sarcocystis* are often found in skeletal muscles and myocardium, where they can form tissue cysts (Dubey et al., 2015). Organs such as the liver and kidney are essential for metabolic processes including detoxification, due to their sensitivity to the action of infectious and environmental factors. Lesions such as lymphocytic hepatitis, hepatic steatosis and interstitial nephritis are described in the literature, changes associated with both

pathological processes and habitat conditions (Beiglböck et al., 2002; Falandysz et al., 2005).
Another study conducted on wild rodents, more specifically on cotton rats (*Sigmodon hispidus*) found in industrial habitats where there are petrochemical deposits; The authors aimed to identify structural lesions in liver and kidney tissue through histopathological evaluation (Kim et al., 2001).
Regarding histopathology, it is an essential method in assessing the effects of biological and environmental stress factors on living organisms, allowing the identification of structural changes at the cellular and tissue level. Histopathological biomarkers, such as inflammation, necrosis, fibrosis and cellular degeneration, are very often used in monitoring the health of wildlife and domestic animals (Au, 2004; Flora et al., 2008).

MATERIALS AND METHODS

This study included 8 wild boars, originating from authorized hunting activities in the Transylvania region, Romania. Regarding the study area, it is characterized by mixed habitat (forest and agricultural), with potential for exposure to biological and environmental factors specific to wildlife. The collection of samples from the wild boar was carried out during the 2023-2024 hunting season, in accordance with national legislation and regulations in force. Of the total of 8 wild boars that we included in the study, both male and female specimens were examined. The distribution by sex was as follows: 5 males and 3 females. A total of 40 tissue samples were collected from 8 wild boars, namely: lungs, heart, liver, kidneys and skeletal muscles. Histopathological tissue lesions were identified with variable frequencies in all examined samples, except for skeletal muscles, where no significant structural changes were observed. Thus, in the study we highlighted only the most relevant lesions. Regarding the tissue samples, they were processed and evaluated from a histological point of view at the Morphopathology Laboratory, Faculty of Veterinary Medicine, University of Agricultural Sciences and Veterinary Medicine Cluj-Napoca, Romania.
Tissue samples were collected during the postmortem examination and fixed in a 10% formalin solution for 24-48 hours. After fixation, they were processed and embedded in paraffin according to the standard paraffin-embedding protocol. The paraffin blocks were then sectioned using a Thermo Scientific HM325 manual microtome, producing 2 µm thick sections. These were mounted on histological slides, incubated at 60°C for 24 hours, stained with hematoxylin-eosin (HE), and examined using an Olympus BX40 microscope. Images were obtained with an Olympus SC180 camera and processed using the cellSens software.

RESULTS AND DISCUSSIONS

This study evaluated the histopathological changes in the main internal organs of wild boars from the Transylvania region, highlighting the presence of lesions of variable intensity in the lung, liver, kidney and heart, while skeletal muscle was unaffected.
Interest in the consumption of game meat, including wild boar, has become a concern at the level of Romania as well. Game meat diversifies the daily diet, being considered a high quality meat if it comes from unpolluted areas. Numerous studies in the specialized literature evaluate the nutritional quality and sustainability of wild boar meat, mentioning the high-quality proteins, the relatively low fat content, the vitamin and mineral content, and all the technological characteristics recommend it for inclusion in a diversified diet (Quaresma et al., 2011; Kasprzyk et al., 2019; Kallas et al., 2021).
We followed the results regarding the lesions at the tissue level, in order to confirm the quality of the boar meat, but also the environment in which it lives.
In the case of the lungs, the histological examination reveled severe inflammatory and necrotic changes, with intralesional presence of multiple parasitic forms, consisting of larvae and adults of *Metastrongylus* spp. They were found inside bronchi and bronchioles, in some cases obstructing the lumen, and leading to desquamation and sloughing of epithelial cells and, in some cases, to the hyperplasia of bronchiolar epithelium. These changes were

accompanied by hyperplasia of bronchial associated lymphoid tissue (BALT) and smooth muscle hyperplasia. Multifocal, we identified peribronchial granulomatous pneumonia, composed of numerous macrophages, lymphocytes, eosinophils and giant multinucleated cells, mixed with fibrosis and congestion. In some cases, the necrotic centre of granulomas presented multiple mineralised foci (Figure 1).

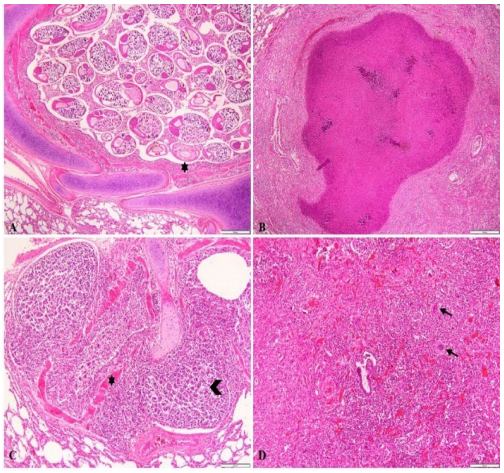

Figure 1. Histological aspect of the pulmonary lesions: A - bronchial obstruction by numerous parasitic forms of *Metastrongylus* spp., with epithelial hyperplasia (star), bar=500 µm; B - peribronchiolar granulomatous pneumonia, bar=500µm; C- hyperplasia of peribronchial associated lymphoid tissue (arrow head) and smooth muscle hyperplasia (star), bar=200µm; D - granulomatous and eosinophilic pneumonia, showing bronchiolar destruction and presence of multiple multinucleated giant macrophages (arrows), bar=200 µm; HE stain (original)

According to the literature, the lung lesions in this study are similar to those of *Metastrongylus* spp. infections in wild boar. These nematodes can colonize the bronchi and bronchioles, causing chronic inflammation, epithelial hyperplasia, eosinophil-rich inflammatory infiltrates and the formation of peribronchial granulomas. In more severe cases, airway obstruction can lead to major lung damage and of course to the appearance of foci of fibrosis and mineralization (Humbert & Henry, 1989; Cabaj et al., 1997).

Regarding the heart, there were no gross changes visible. Histologically, the only lesions was the presence of multiple protozoal cyst (*Sarcocystis* spp.) expanding the cardiomyocytes. These cysts consisted of a thin, hyalinized, acellular membrane that contained a myriad of bradyzoites. The muscle fibres were, occasionally swollen, with a hypereosinophilic sarcoplasm. There were no inflammatory infiltrates observed (Figure 2).

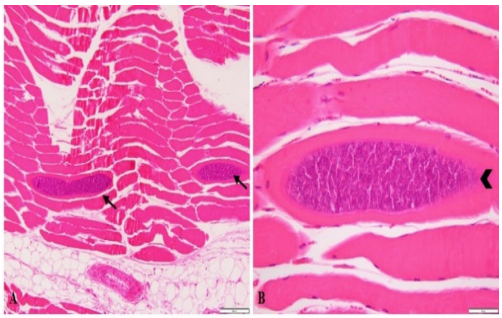

Figure 2. Histological aspect of the miocardial lesions: A - *Sarcocystis* cysts inside cardiomyocytes (arrows) containing numerous bradyzoites, bar=200µm; B - peribronchiolar granulomatous pneumonia, bar=50µm; HE stain (original)

Sarcocystis spp. cysts observed in the myocardium are associated with minimal degenerative changes in cardiomyocytes and the absence of inflammatory infiltrates. These observations are consistent with studies showing that cardiac sarcocystosis in wild boar is frequently a subclinical infection, characterized by the presence of intramuscular cysts without an essential inflammatory reaction from the host (Odening, 1998; Dubey et al., 2015).

The lesions present in the liver parenchyma were mild, and consisted of multiple foci of inflammatory infiltrate, with mononuclear cells, mainly lymphocytes. In some individuals we identified many intracytoplasmic clear vacuoles, of different sizes, causing cellular augmentation and multifocal necrosis (hepatic steatosis). When present, this lesion was diffuse and severe. The etiology of this degeneration is believed to be nutritional (influenced by the diet, feeding habits of wild boars, obesity), metabolic (hypothyroidism, adrenal pathologies) or circulatory (hypoxia related steatosis) (Figure 3).

In the case of the hepatic changes observed in the study, namely focal lymphocytic infiltrates and hepatic steatosis, these changes have also been reported in other wild boar populations. We also mention that the liver is an organ with

an important role in metabolic and detoxification processes, being frequently affected by all nutritional imbalances, metabolic changes or exposure to various environmental stress factors. Hepatocyte vacuolization and lipid accumulation may represent common changes described in wild animals under metabolic stress (Cullen & Stalker, 2016).

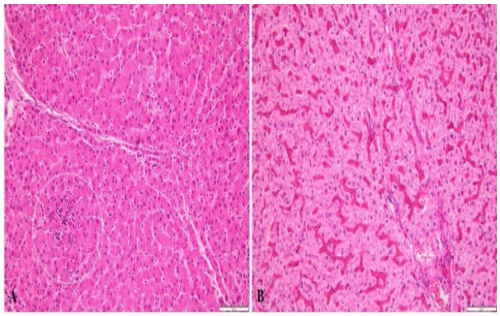

Figure 3. Histological aspect of the hepatic lesions: A - focal minimal lymphocytic hepatitis (circled area); B - diffuse severe hepatic steatosis; HE stain, bar=100 µm (original)

Multifocally, the renal parenchyma was distended by a moderate inflammatory infiltrate, composed of lymphocytes, histiocytes and a small number of plasma cells, located interstitially and perivascular. This change was present both in the cortex and the medulla, sparing the renal pelvis. Though no microbiology culture was performed in these cases, it is possible that these changes were brought on by chronic infectious diseases (Figure 4).

The lymphohistiocytic interstitial nephritis observed in our study is comparable to lesions described in cervids and other wildlife species exposed to various infectious agents or multiple external environmental factors. This lesion usually indicates a chronic but persistent inflammatory process, characterized by infiltration of the renal interstitium with mononuclear cells and long-term impairment of renal function (Beiglböck et al., 2002).

In the case of the muscle tissue in our study, the histopathological examination revealed no changes or cellular damage, suggesting that the muscle is safe for food consumption from this region.

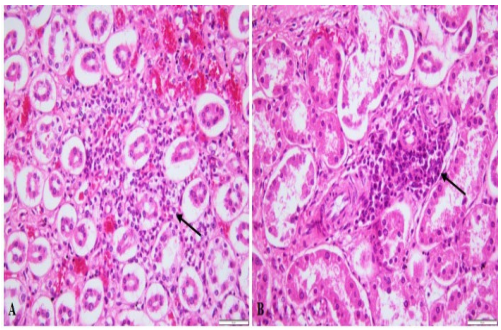

Figure 4. Histological aspect of the renal lesions: A, B - Moderate, multifocal, lympho-histiocytic interstitial nephritis; HE stain, bar=50µm (original)

Regarding the absence of muscle lesions, it is an essential result, especially from a food safety perspective. Therefore, according to studies in the specialized literature, skeletal muscle is usually less affected by chronic pathological processes or even by local accumulation of contaminants, being also the most consumed organ by the human population (Amici et al., 2012; Kallas et al., 2021).

CONCLUSIONS

The histopathological examination in this study revealed lesions with varying degrees of severity in the lungs, liver, kidneys and heart of the examined wild boars, while the skeletal muscles did not show significant changes. Pulmonary lesions associated with infestation with *Metastrongylus* spp. represented the most important pathological changes identified in the present study.

Sarcocystis spp. cysts were observed in the myocardium, and chronic inflammatory processes and degenerative changes were highlighted in the liver and kidneys. It is worth mentioning that the absence of significant lesions for the skeletal muscles indicates a good structural integrity of this tissue intended for human consumption. Our results emphasize the importance of constant monitoring of wild boar populations through histopathological examinations, as a useful tool in disease surveillance and environmental quality assessment.

REFERENCES

Amici, A., Danieli, P. P., Russo, C., Primi, R., & Ronchi, B. (2012). Concentrations of some toxic and trace elements in wild boar (*Sus scrofa*) organs and tissues in different areas of the Province of Viterbo, Central Italy. *Italian Journal of Animal Science, 11*(4), e65.

Au, D. W. T. (2004). The application of histo-cytopathological biomarkers in marine pollution monitoring: A review. *Marine Pollution Bulletin, 48*(9–10), 817–834.

Beiglböck, C., Steineck, T., Tataruch, F., Ruf, T., & Krone, O. (2002). Age-related and seasonal variations of cadmium concentration and pathological changes in kidneys of roe deer (*Capreolus capreolus*). *Archives of Environmental Contamination and Toxicology, 42*(1), 91–97.

Cabaj, W., Moskwa, B., Pastusiak, K., & Bien, J. (1997). Wild boars as reservoirs of parasitic infections in Poland. *Wiadomości Parazytologiczne, 43*(4), 517–521.

Cullen, J. M., & Stalker, M. J. (2016). Liver and biliary system. In Maxie, M. G. (Ed.), *Jubb, Kennedy and Palmer's Pathology of Domestic Animals,* 6th ed., Vol. 2, pp. 258–352, Elsevier.

Dubey, J. P., Calero-Bernal, R., Rosenthal, B. M., Speer, C. A., & Fayer, R. (2015). *Sarcocystosis of Animals and Humans* (2nd ed.). Boca Raton, USA: CRC Press Publishing House.

Falandysz, J., Szymczyk-Kobrzyńska, K., Brzostowski, A., Zalewski, K., & Zasadowski, A. (2005). Concentrations of heavy metals in the tissues of red deer (*Cervus elaphus*) from the region of Warmia and Mazury, Poland. *Food Additives and Contaminants, 22*(2), 141–148.

Flora, S. J. S., Mittal, M., & Mehta, A. (2008). Heavy metal induced oxidative stress and its possible reversal by chelation therapy. *Indian Journal of Medical Research, 128*(4), 501–523.

García-González, Á. M., Pérez-Martín, J. E., Gamito-Santos, J. A., & Calero-Bernal, R. (2013). Epidemiologic study of lung parasites (*Metastrongylus* spp.) in wild boar (*Sus scrofa*) in southwestern Spain. *Journal of Wildlife Diseases, 49*(1), 157–162

Humbert, J. F., & Henry, C. (1989). Studies on the prevalence and pathology of *Metastrongylus* infections in wild boars (*Sus scrofa*) in France. *Veterinary Parasitology, 31*(3-4), 261–270.

Kallas, Z., Serra, T., Gil, J. M., & Realini, C. E. (2021). Wild boar meat as a sustainable substitute for pork: A mixed methods approach. *Sustainability, 13*(5), 2490.

Kasprzyk, A., Stasiak, D. M., & Babicz, M. (2019). Meat quality and nutritional value of wild boar meat. *Animal Science Papers and Reports, 37*(3), 225–233.

Kim, S., Lochmiller, R. L., Stair, E. L., Lish, J. W., Rafferty, D. P., & Qualls, C. W. (2001). Efficacy of histopathology in detecting petrochemical-induced toxicity in wild cotton rats (*Sigmodon hispidus*). *Environmental Pollution, 113*(3), 323–329.

Martin, S., & Griswold, W. (2009). Human health effects of heavy metals. *Environmental Science and Technology Briefs for Citizens, 15*, 1–6.

Odening, K. (1998). The present state of species-systematics in *Sarcocystis* Lankester, 1882 (Protozoa, Apicomplexa, Coccidia). *Systematic Parasitology, 41*(3), 209–233.

Quaresma, M. A. G., Alves, S. P., Trigo-Rodrigues, I., Pereira-Silva, R., Santos, N., Lemos, J. P. C., Barreto, A. S., & Bessa, R. J. B. (2011). Nutritional evaluation of the lipid fraction of feral wild boar (*Sus scrofa scrofa*) meat. *Meat Science, 89*(4), 457–461.

Rule, D. C., Broughton, K. S., Shellito, S. M., & Maiorano, G. (2002). Comparison of muscle fatty acid profiles and cholesterol concentrations of bison, beef cattle, elk, and chicken. *Journal of Animal Science, 80*, 1202–1211.