Scientific Papers. Series D. Animal Science. Vol. LXIX, No. 1, 2026
ISSN 2285-5750; ISSN CD-ROM 2285-5769; ISSN Online 2393-2260; ISSN-L 2285-5750

# HISTOMORPHOLOGICAL HEPATIC ALTERATIONS IN *Squalius cephalus* (Linnaeus, 1758) EXPOSED TO HEAVY METALS: A CROSS-WATERSHED COMPARATIVE STUDY OF TWO ROMANIAN RIVERS

**Maria-Cătălina MATEI-LAȚIU[1, 2], Călin LAȚIU[3], Tudor PĂPUC[2, 3], George-Cătălin MUNTEAN[2, 3], Adela Maria DĂESCU[1, 2], Anca BECZE[4], Claudiu TĂNĂSELIA[4], Lăcrimioara ȘENILA[4], Vasile RUS[1], Adrian Florin GAL[1]**

[1]Faculty of Veterinary Medicine, Department of Cell Biology, Histology and Embryology, University of Agricultural Sciences and Veterinary Medicine of Cluj-Napoca, 3-5 Calea Mănăștur, 400372, Cluj-Napoca, Romania
[2]Academy of Romanian Scientists, Ilfov 3, 050044 Bucharest, Romania
[3]Faculty of Animal Science and Biotechnologies, University of Agricultural Sciences and Veterinary Medicine of Cluj-Napoca, 3-5 Calea Mănăștur, Cluj-Napoca, 400372, Romania
[4]INCDO-INOE 2000, Research Institute for Analytical Instrumentation, 67 Donath Street, 400293, Cluj-Napoca, Romania

Corresponding author email: calin.latiu@usamvcluj.ro

***Abstract***

*Heavy metal pollution poses a major threat to freshwater ecosystems and aquatic organisms. This study investigates liver histomorphology in chub (Squalius cephalus), a sentinel species, from two Romanian rivers with contrasting contamination levels: the Arieș River in the Roșia Montană area, a basin heavily affected by long-term mining, and the unpolluted Hășdate River. Water analyses confirmed significant metal contamination in the Arieș River and clean conditions in the Hășdate River. Hepatic tissue was collected, histologically processed by the routine paraffin embedding technique, and stained with Goldner's trichrome to assess structural integrity. Livers from Hășdate fish displayed normal hepatic architecture, whereas hepatic samples collected from the Arieș River exhibited histopathological alterations, including vascular adaptations (hyperaemia), degenerative lesions (vacuolar/lipidic or hydropic degenerations) and extended necrotic lesions. These findings demonstrate that chronic exposure to heavy metal-contaminated waters induce clear structural changes in fish livers, highlighting hepatic histology as a sensitive biomarker for aquatic pollution. The study provides insights into ecosystem health and supports the use of fish liver histopathology for environmental monitoring and risk assessment, offering a model for evaluating pollution impacts in freshwater systems globally.*

***Key words****: freshwater ecosystems, heavy-metal contamination, histopathology, sentinel species.*

## INTRODUCTION

Aquatic ecosystems are increasingly threatened by anthropogenic pollution, particularly by heavy metals originating from industrial and mining activities. In recent years, fish histopathology has become a widely recognized and reliable tool for ecological risk assessment and biomonitoring of aquatic environments (Yancheva et al., 2016; Reddy & Rawat, 2013). Once toxicants cross biological barriers and enter the bloodstream, they are distributed to internal organs, where they may accumulate and induce structural damage (Yancheva et al., 2016). Among fish organs, the liver is considered one of the most informative targets for environmental assessment due to its central role in detoxification, metabolism, and excretion of xenobiotics (Hinton & Laurén, 1990; van der Oost et al., 2003; Salamat & Zarie, 2012; Yancheva et al., 2016). Owing to its high vascularization and metabolic activity, the liver is frequently identified as a primary organ for bioaccumulation and toxicant-induced injury (Yancheva et al., 2016; Georgieva et al., 2016). Histopathological evaluation provides a sensitive and integrative biomarker of exposure, reflecting both short- and long-term toxic effects, and has therefore been incorporated into environmental monitoring

programs worldwide (Yancheva et al., 2016; Reddy & Rawat, 2013).

In healthy teleost fish, the liver exhibits a typical parenchymatous architecture without pathological abnormalities (Vicenti et al., 2005; Figueiredo-Fernandes et al., 2007; Yancheva et al., 2016). The hepatic parenchyma is primarily composed of polygonal hepatocytes containing a centrally located, large spherical nucleus and homogeneous cytoplasm. These cells are arranged in cord-like structures separated by sinusoidal capillaries, whose lumen predominantly contain erythrocytes (Yancheva et al., 2016). The sinusoids are lined by reticuloendothelial cells and are supplied by venous blood entering caudally from the intestine via the hepatic portal vein system (Yancheva et al., 2016). Preservation of this structural organization is generally indicative of good environmental quality and physiological homeostasis.

Exposure to metals and other xenobiotics can induce a wide spectrum of hepatic alterations in fish, many of which are considered reliable biomarkers of toxic damage (Stentiford et al., 2003; Yancheva et al., 2016). Degenerative changes such as vacuolar, hydropic, and fatty degeneration are frequently reported and are associated with biochemical disturbances including impaired protein synthesis, altered enzymatic activity, disruption of ion regulation, and energy depletion (Monteiro et al., 2005; Rajeshkumar & Munuswamy, 2011; Yancheva et al., 2016). Hydropic vacuolation may result from disruption of volume-regulating ATPases and ionic imbalance (Hinton & Laurén, 1990; Yancheva et al., 2016) and has been documented in multiple fish species exposed to contaminants (Stehr et al., 1998; Lang et al., 2006; Yancheva et al., 2016). Lipid accumulation within hepatocytes, characterized by clear cytoplasmic vacuoles, has similarly been associated with toxicant exposure and metabolic disturbance (Marty et al., 2003; Pinto et al., 2009; Yancheva et al., 2016). More severe alterations include hyperemia, necrosis, inflammatory infiltrates, and architectural disorganization of the hepatic parenchyma (Yancheva et al., 2016; Reddy & Rawat, 2013). Necrosis, in particular, is regarded as one of the most serious structural changes and is commonly associated with metal exposure (Yancheva et al., 2016). Previous investigations conducted in Romanian rivers have demonstrated correlations between metal accumulation and histopathological alterations in the liver of European chub *Squalius cephalus* (Linnaeus, 1758) and other indigenous species (Triebskorn et al., 2008).

The Roșia Montană area, situated within the Arieș River Basin in Romania, represents one of Europe's most historically significant mining regions, with exploitation activities dating back to the Dacian Kingdom and intensifying during Roman times (Bănăduc et al., 2021). Mining activities continued throughout the Middle Ages and into the modern era, leaving persistent environmental impacts (Bănăduc et al., 2021). Metal pollution derived from ore extraction and processing is of particular concern due to the persistence, stability, and bioaccumulative properties of heavy metals (Georgieva et al., 2016). Metals released from mining operations can enter surface waters, where they accumulate in sediments and aquatic organisms, posing risks to ecosystem integrity and fish health (Georgieva et al., 2016).

Given the documented sensitivity of fish liver histopathology to metal exposure and the historical mining pressure in the Roșia Montană region, the present study aimed to comparatively evaluate hepatic histological alterations in European chub (*Squalius cephalus*) collected from two rivers differing in heavy metal pollution status. Specifically, we compared the liver architecture of fish inhabiting a river affected by industrial and mining-derived contamination with that of fish from a reference, non-polluted river, in order to assess the extent to which environmental metal exposure is reflected in hepatic structural integrity.

## MATERIALS AND METHODS

### Sampling site

With the help of thorough bibliographic studies (Glevitzky et al., 2025; Levei et al., 2011; Dumitrel et al., 2015; Bird et al., 2005; Bănăduc et al., 2021), several geographical areas crossed by major watercourses and sharing similar climatic characteristics were identified. Subsequently, field surveys were

carried out in these areas. Two Romanian rivers with contrasting contamination levels were selected: the Arieș River in the Roșia Montană area, a basin heavily affected by long-term mining (Bănăduc et al., 2021), and the unpolluted Hășdate River. In order to have a comparable environment from a climatic point of view, before selecting the rivers, inclusion and exclusion criteria were created. The main characteristics considered were the pollution potential of the area (taking into account whether the watercourse crosses an industrial area upstream—such as mining operations, coal-fired power plants, or waste disposal facilities), ease of access for different fishing methods (parameters such as water depth, discharge, and bank slope were analyzed), as well as the possibility of retaining catches of legal size limit for each specimen. Specifically, the inclusion and exclusion criteria for each river category are presented in Table 1.

Table 1. Specific and common inclusion and exclusion criteria for the selection of two contrasting rivers in terms of industrial pollution

| | **River category** | | | |
|---|---|---|---|---|
| | **Positive control** (industrially polluted with heavy metals) | | **Negative control** (not industrially polluted with heavy metals) | |
| | Inclusion criteria | Exclusion criteria | Inclusion criteria | Exclusion criteria |
| Specific | Crosses an industrial area upstream | Absence of a clearly identifiable industrial area upstream | Does not cross an industrial area upstream | Presence of a clearly identifiable industrial area upstream |
| Common | Inclusion criteria | | Exclusion criteria | |
| | Easy access | | Lack of access to the watercourse | |
| | Possibility of retaining catches | | Biological conservation area or catch-and-release (C & R) fishing area | |
| | Climate & hydrology – moderate continental | | Different climatic regime | |
| | Approximate altitude – 400-600 m | | High altitude (mountain areas) or low altitude (near 0 m) | |
| | Aquatic fauna – chub (*Squalius cephalus*) present in fish surveys | | Area unsuitable for the presence of chub | |

**Water evaluation**

*In situ analyses - determination of temperature and pH*: Water temperature was measured using a portable thermometer (Hanna Checktemp 4, model HI151), while pH was determined with a portable pH meter (Hanna pHep+ model HI98108). Both parameters were measured in triplicate at the sites from which water and substrate samples were subsequently collected.

*Sample collection for heavy metal pollution assessment*: For the determination of heavy metal concentrations, three water samples and three substrate samples were collected from each river site. Water samples were collected in accordance with the guidelines provided by the reference laboratory, using sterile glass containers. Substrate samples were collected using hermetically sealed plastic bags. All collected samples were refrigerated and transported to the laboratory on the day of sampling. The water samples were filtered through 0.45 µm cellulose acetate membrane filters and acidulated with 65% $HNO_3$ to pH<2. An amount of 3 g sample was digested with aqua regia (HCl 37%: HNO3 65%, 3:1, v:v), filtered and diluted to 100 mL with ultra-pure water (Elga Veolia, High Wycombe, UK) according to ISO 11466. Each sample was prepared in triplicate. A Thermo Fisher Scientific iCAP TQ inductively coupled plasma mass (ICP-MS) spectrometer was used for elemental analysis. The instrument was tuned before the batch run and optimized for high signal and low noise, while making sure the double ionization and oxides level were kept under control. Multi-element ICP-MS standard was purchased for Perkin Elmer for calibration solutions and a 4-point plus blank calibration curve was used for the analysis (with respective concentration of 10-20-50-100 ppb for each element). To ensure no polyatomic or isobaric interference would alter the result, two interference removal techniques were used in the collision reaction cell: kinetic energy discrimination (KED, by using a Helium flow inside the cell) for most elements and mass-shift (by using an Oxygen flow inside the cell)

for elements where KED is known to be ineffective, namely Sc, V, As, Se, Sr.

**Biological material**

The European chub *Squalius cephalus* (Linnaeus, 1758) has been shown to function effectively as a sentinel species in environmental monitoring studies (Hájková et al., 2007; Havelkova et al., 2008; Krywult et al., 2008). A total of 15 European chub were collected for the present study between July and September 2025 using spinning gear with artificial lures. Only adult specimens exceeding 25 cm in total length (the minimum legal size) were selected. The fish were humanely euthanized immediately after capture by administerring an overdose of *Eugenia cariophilata* extract in water. Shortly thereafter, anatomical dissections were performed and liver tissues were excised. All collected samples were promptly fixed in 10% buffered formalin.

**Histological assessment**

Histological analyses were performed in the histology laboratory of the Faculty of Veterinary Medicine, University of Agricultural Sciences and Veterinary Medicine Cluj-Napoca, Romania. Following collection, samples were fixed for five days, after which liver tissues were processed according to standard paraffin-embedding protocols. Serial sections with a thickness of 5 µm were obtained using a rotary microtome (Leica rotary microtome, Germany). The sections were subsequently stained using Goldner's trichrome method, following established procedures (Suvarna et al., 2018). Microscopic examination was carried out using an Olympus BX41 light microscope equipped with an Olympus SC180 digital camera (Olympus, Japan), and image acquisition and analysis were performed with Olympus CellSens software.

Histopathological evaluation: All microscopic preparations were independently examined by two pathologists, and the observed lesions were identified, recorded, and classified accordingly.

**Statistical analysis**

The obtained data were processed statistically processed, usingMS Office/Excel and GraphPad Prism 8 software.

Heavy metal concentrations below the analytical *limit of detection* (LOD) were treated as left-censored data and substituted with LOD/2 prior to statistical analysis. This approach was applied when the proportion of values below LOD was low and is commonly used in environmental contamination studies to reduce bias associated with zero substitution (Hornung & Reed, 1990). Heavy metal concentrations (determined in µg/L for water samples and mg/kg for sediment/soil samples) often exhibit high variability and are typically positively skewed, with a small number of samples showing very high concentrations while most remain low. All raw concentration data were log-transformed ($\log_{10}$) prior to analysis. This transformation also helps to reduce the influence of extreme outliers and stabilizes variance across the data range (Reimann & Filzmoser, 2000). Due to the high dimensionality of the dataset (25 elements) and the wide range of concentrations spanning several orders of magnitude, all raw data were subjected to a logarithmic transformation ($y = \log_{10} y$) prior to analysis. This procedure was essential to normalize the data distribution and ensure homoscedasticity across the variables.

To evaluate the environmental dynamics between the polluted (Positive Control River - PCR) and control (Negative Control River - NCR) rivers, three distinct sets of comparisons were conducted: (a) partitioning between the water column and the substrate within each site, (b) comparison of dissolved metals between sites, and (c) comparison of substrate-bound metals between sites.

Statistical significance for each of the 25 elements was determined using Multiple t-tests (one per row). To account for the multiple testing problem and control the family-wise error rate, the Benjamini-Hochberg FDR was applied to adjust *p*-values and identify significant "discoveries." The threshold for statistical significance was set at $p < 0.05$. All results are expressed as Mean Standard Error of the Mean (SEM) (n = 3). Graphical representations were generated as interleaved bar charts on a scale to facilitate the visual assessment of multi-elemental partitioning.

## RESULTS AND DISCUSSIONS

**Positive control river (industrially polluted with heavy metals)**

Following field surveys and the application of the previously presented inclusion/exclusion criteria, the Arieș River in the Roșia Montană area (at the confluence with local tributaries – Abrudel, Roșia, Valea Șesii), was selected as the positive control hydrographic basin (industrially polluted with heavy metals). From a climatic and hydrological perspective, this watercourse exhibits a regime characterized by a moderate continental climate and a pluvio-nival hydrological influence. In this region as well, these environmental characteristics are conducive to the presence of chub (*Squalius cephalus*) in the aquatic fauna (Mireșan et al., 2016).

**Negative control river (not industrially polluted with heavy metals)**

Following field surveys and the application of the previously presented inclusion/exclusion criteria, the Hășdate River was selected as the negative control hydrographic basin (not industrially polluted with heavy metals). This river spans altitudes ranging from approximately 400 m at the exit of the gorge to over 600-700 m in the mountainous sector. The region experiences a moderate continental climate, with substantial precipitation in spring and summer and winters characterized by a moderate snow cover (approximately 25-65 days per year). The hydrological regime is mixed, pluvio-nival, with potential flood events occurring in spring due to snowmelt and after intense summer rainfall. These hydrological and ecological characteristics are also conducive to the presence of chub (*Squalius cephalus*) (Mireșan et al., 2016).

**Water parameters**

*Water temperature*: In the positive control watercourse, the mean recorded water temperature was 20.46 ± 0.12°C (Figure 1). For the negative control watercourse (Hășdate River), the mean water temperature was 20.53 ± 0.04°C. Measurements were carried out at an interval of 10 days, both in June 2025, under sunny conditions and in the absence of precipitation in the preceding days.

*Water pH*: In the positive control watercourse the mean pH was 6.33 ± 0.36, whereas in the negative control watercourse, the mean pH value was 7.40 ± 0.08 (Figure 1). As for temperature, pH measurements were performed 10 days apart, both in June 2025, during sunny weather and with no rainfall recorded in the days prior to sampling.

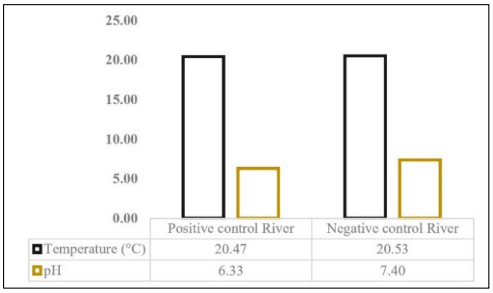


Figure 1. Comparison of mean water temperature and pH between the positive (industrially heavy metal–polluted) and negative (unpolluted) control rivers

*Heavy metals contamination*: In terms of heavy metal concentrations in water samples from the positive control river, manganese (Mn) and iron (Fe) levels markedly exceeded the threshold values established for Class V (very poor quality) surface waters (MMGA, 2006). Specifically, Mn reached 1429.4 µg/L, compared with the Class V limit of >1000 µg/L, while Fe concentrations were 7937.7 µg/L, substantially surpassing the corresponding limit of >2000 µg/L. In contrast, concentrations of the analyzed elements in the negative control river were considerably lower, resulting in its classification within Class I or, at most, Class II water quality, indicative of an essentially unpolluted system. Furthermore, comparative analysis between the two rivers revealed higher concentrations of Li, Mg, Al, Co, Ni, Cu, Zn, and As in the positive control river relative to the negative control. For both watercourses, concentrations of Be, Co, Ga, Se, Ag, Cd, In, Cs, Tl, Bi, and Hg were below the analytical limit of detection (<1.0 µg/L) (Table 2).

**Positive control river results (water vs. sediment)**

The comparison between dissolved metals in the water column (W-PCR) and the sedimentary substrate (S-PCR) at the polluted site

revealed a strong preferential accumulation in the solid phase. Statistical analysis using Multiple t-tests identified several significant 'discoveries' where substrate concentrations far exceeded those in the water column ($p < 0.001$). A prominent example was gallium (Ga), which exhibited a highly significant difference ($p = 0.000076$), with substrate concentrations approximately 40 times higher than those recorded in the water column (Difference = -1.597log10 units). Similar trends of sedimentary enrichment were observed for major elements such as aluminium (Al), iron (Fe), and lead (Pb). This distinct partitioning pattern confirms that the substrate in the PCR river acts as the primary reservoir for the heavy metal load, effectively sequestering contaminants from the aqueous phase (Figure 2).

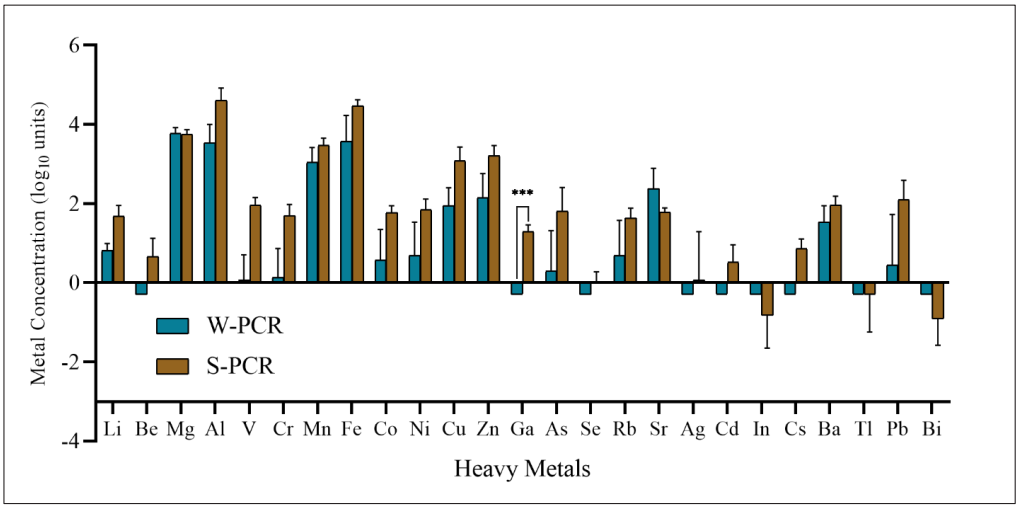


Figure 2. Comparative analysis of heavy metal concentrations in water (W-PCR) and sediment (S-PCR) samples from the Positive Control River. Data are presented on a logarithmic scale (log10 units, µg/L for water samples and mg/kg for sediment samples) to account for the wide range of elemental concentrations. Error bars represent the standard deviation (SD)

**Negative control river results (water vs. sediment)**

At the NCR site, statistical analysis using Multiple t-tests identified a specific group of trace elements that remained predominantly in the aqueous phase rather than accumulating in the substrate. Selenium (Se), silver (Ag), indium (In), strontium (Sr), cesium (Cs), and thallium (Tl) all exhibited significantly higher concentrations in the water column compared to the sedimentary matrix ($p < 0.01$). The most robust statistical differences were recorded for Se, Ag, and In, which maintained concentrations in the water exactly one order of magnitude higher than in the substrate (Difference = 1.00 log10 units, $p < 0.00000.1$). Strontium (Sr) showed the most substantial divergence, with aqueous levels being approximately 26.5 times higher than those found in the substrate (Difference = 1.424 log10 units, $p < 0.0001$). Furthermore, thallium (Tl) and cesium (Cs) concentrations were 14.2 and 5.5 times higher in the water phase, respectively ($p < 0.002$), indicating a high degree of elemental persistence in the water column of the NCR site (Figure 3).

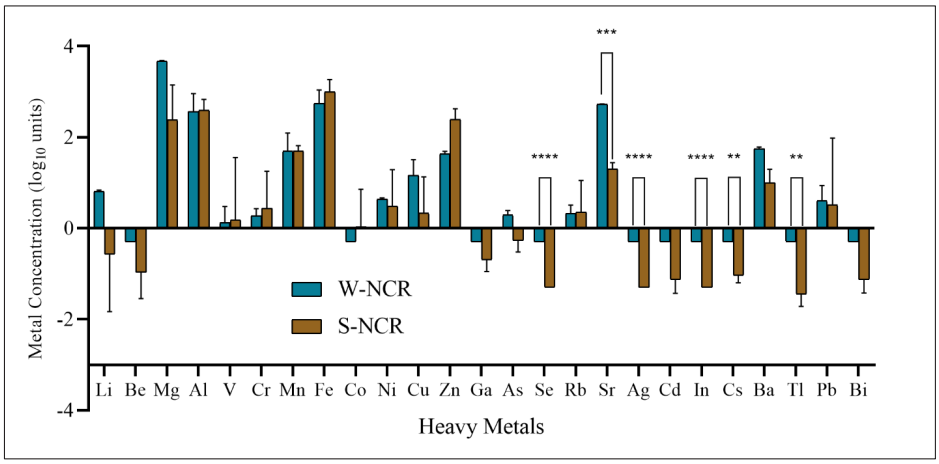


Figure 3. Comparative analysis of heavy metal concentrations in water (W-NCR) and sediment (S-NCR) samples from the Negative Control River. Data are presented on a logarithmic scale (log10 units, µg/L for water samples and mg/kg for sediment samples) to account for the wide range of elemental concentrations. Error bars represent the standard deviation (SD)

**Positive control river vs. negative control river water samples comparisons**

The comparison of dissolved metal concentrations between the polluted river (PCR) and the negative control river (NCR) showed that, although several elements exhibited higher mean values in the polluted site, no statistically significant 'discoveries' were identified after False Discovery Rate (FDR) correction ($q > 0.05$). Visually, manganese (Mn), aluminium (Al), and iron (Fe) showed the most prominent increases in the W-PCR samples compared to W-NCR. Specifically, manganese reached a *p*-value of 0.0126 and aluminium 0.0512. However, these did not meet the stringency requirements for multiple comparisons across all 25 elements. For highly toxic elements such as cadmium (Cd), lead (Pb), and arsenic (As), concentrations remained relatively low or below the limit of detection (LOD) in both river systems, suggesting that the dissolved phase might not fully reflect the anthropogenic impact at the time of sampling (Figure 4).

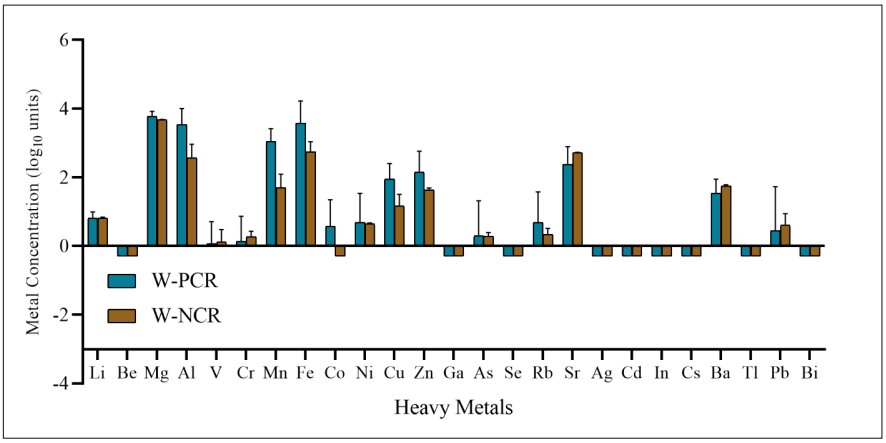


Figure 4. Comparative analysis of heavy metal concentrations in water samples from the Positive Control River (W-PCR) and the Negative Control River (W-NCR). Data are presented on a logarithmic scale (log10 units, µg/L for water samples and mg/kg for sediment samples) to account for the wide range of elemental concentrations. Error bars represent the standard deviation (SD)

**Positive control river vs. negative control river sediment samples comparisons**

The analysis of the sedimentary substrate provided the most definitive evidence of environmental contamination at the polluted PCR site. Unlike the water column, the substrate samples exhibited a distinct 'pollution fingerprint' for several key elements. Statistical analysis using Multiple t-tests on $log_{10}$-transformed data identified six statistically significant discoveries (Al, Mn, Fe, Ga, Se, and Cs) with $q < 0.05$ (FDR corrected). The most dramatic enrichment was observed for aluminium (Al) and gallium (Ga), which exhibited concentrations approximately 100 times higher in the S-PCR substrate compared to the NCR reference site (Differences of 2.02 and 1.99 $log_{10}$ units, respectively; $p < 0.001$). Furthermore, manganese (Mn) and cesium (Cs) showed massive accumulation in the polluted sediments, with concentrations nearly 60 to 80 times higher than those in the clean river ($p<0.0005$). Other major elements, such as iron (Fe), also showed significant enrichment in the PCR site (Difference = 1.469; $p = 0.0012$), confirming the role of the PCR substrate as a major long-term sink for anthropogenic pollutants (Figure 5).

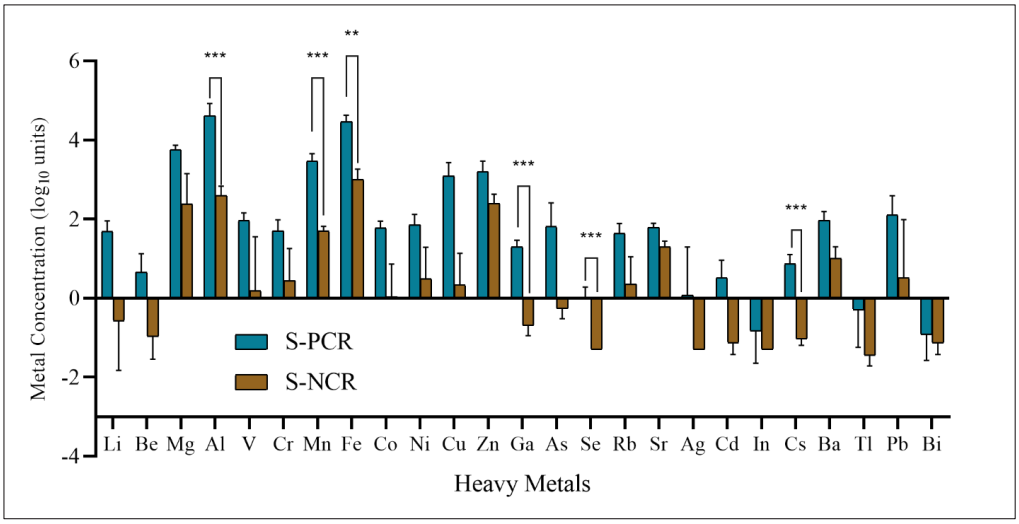


Figure 5. Comparative analysis of heavy metal concentrations in sediment samples from the Positive Control River (S-PCR) and the Negative Control River (S-NCR). Data are presented on a logarithmic scale (log10 units, µg/L for water samples and mg/kg for sediment samples) to account for the wide range of elemental concentrations. Error bars represent the standard deviation (SD)

Regarding heavy metal concentrations in sediment samples, current legislation does not specify threshold values for pollution classification. Nevertheless, the results of the present study indicate that, in comparative terms, metal concentrations in sediments from the positive control river were consistently higher than those measured in the negative control river. Furthermore, in the positive control river, none of the analyzed elements were below the analytical limit of detection (0.10 mg/kg), whereas in sediments from the negative control river, selenium (Se), silver (Ag), and indium (In) were below the limit of detection (Table 2).

Table 2. Heavy metal concentrations in water and sediment samples from the positive and negative control rivers

| | Positive control river (PCR) | | Negative control river (NCR) | |
|---|---|---|---|---|
| | Water samples W-PCR (ug/L) | Sediment samples S-PCR (mg/kg) | Water samples W-NCR (ug/L) | Sediment samples S-NCR (mg/kg) |
| Li | 6.79 | 54.86 | 6.48 | 7.34 |
| Be | <LOD | 6.31 | <LOD | 0.50 |
| Mg | 6129.67 | 5785.22 | 4706.32 | 675.14 |
| Al | 4857.72 | 47241.84 | 458.27 | 435.17 |
| V | 6.38 | 97.69 | 2.13 | 13.74 |
| Cr | 9.52 | 57.62 | 1.95 | 8.54 |
| Mn | 1429.36 | 3125.62 | 61.91 | 50.90 |
| Fe | 7937.67 | 30546.79 | 638.10 | 1130.08 |
| Co | 10.89 | 63.06 | <LOD | 3.49 |
| Ni | 15.04 | 80.94 | 4.40 | 9.27 |
| Cu | 124.17 | 1506.10 | 18.31 | 6.49 |
| Zn | 260.13 | 1791.64 | 43.47 | 272.74 |
| Ga | <LOD | 20.81 | <LOD | 0.23 |
| As | 29.81 | 99.87 | 1.98 | 0.59 |
| Se | <LOD | 1.18 | <LOD | <LOD |
| Rb | 17.27 | 48.27 | 2.25 | 5.35 |
| Sr | 392.62 | 62.47 | 529.27 | 20.66 |
| Ag | <LOD | 6.94 | <LOD | <LOD |
| Cd | <LOD | 4.32 | <LOD | 0.16 |
| In | <LOD | 1.28 | <LOD | <LOD |
| Cs | <LOD | 8.15 | <LOD | 0.10 |
| Ba | 43.76 | 100.63 | 56.40 | 11.74 |
| Tl | <LOD | 2.24 | <LOD | 0.02 |
| Pb | 83.89 | 174.19 | 4.81 | 54.55 |
| Bi | <LOD | 0.70 | <LOD | 0.16 |

Note: LOD - limit of detection (1.0 µg/L for water samples and 0.1 mg/kg for sediment samples).

**Histological results**

Histopathological examination of liver tissue from chub (*Squalius cephalus*) revealed clear differences between specimens collected from the negative and positive control rivers (Figure 6). Fish from the negative control river exhibited normal hepatic architecture, characterrized by well-organized hepatocytes arranged in cord-like structures and separated by narrow sinusoidal capillaries (Figure 6A).

In contrast, liver tissue from fish collected in the positive control river showed multiple and pronounced pathological alterations. Hepatocytes exhibited both lipid (steatotic) and hydropic degeneration, evidenced by marked cytoplasmic vacuolization and cellular swelling (Figure 6B, C, F, I; black arrows). Vascular disturbances were frequently observed, including sinusoidal dilation and congestion consistent with hyperemia (Figure 6D, E, F, G, H; empty arrows).

Numerous hepatocytes displayed morphological features indicative of apoptosis (Figure 6G; arrowheads), while focal areas of hepatocellular necrosis were also present (Figure 6G, H, I; dashed rectangles). These degenerative and vascular changes were accompanied by a loss of normal hepatic architecture, with disruption of the cord-like arrangement of hepatocytes and a markedly disorganized parenchyma (Figure 6H; dashed circle). In more advanced lesions, these alterations frequently co-occurred within the same tissue sections, indicating progressive hepatic damage.

Collectively, these alterations indicate substantial structural impairment of liver tissue in fish from the heavy metal-polluted river. In contrast, liver sections from chub sampled in the negative control river showed preserved histological organization and features consistent with normal hepatic tissue. Hepatocytes were arranged in regular cords separated by narrow, non-dilated sinusoidal capillaries, with no evidence of vascular congestion. The cells displayed a typical polygonal shape, an acidophilic cytoplasm, and centrally located

spherical nuclei, present as either single or occasionally binucleated. No degenerative, apoptotic, or necrotic alterations were detected in these samples (Figure 6).

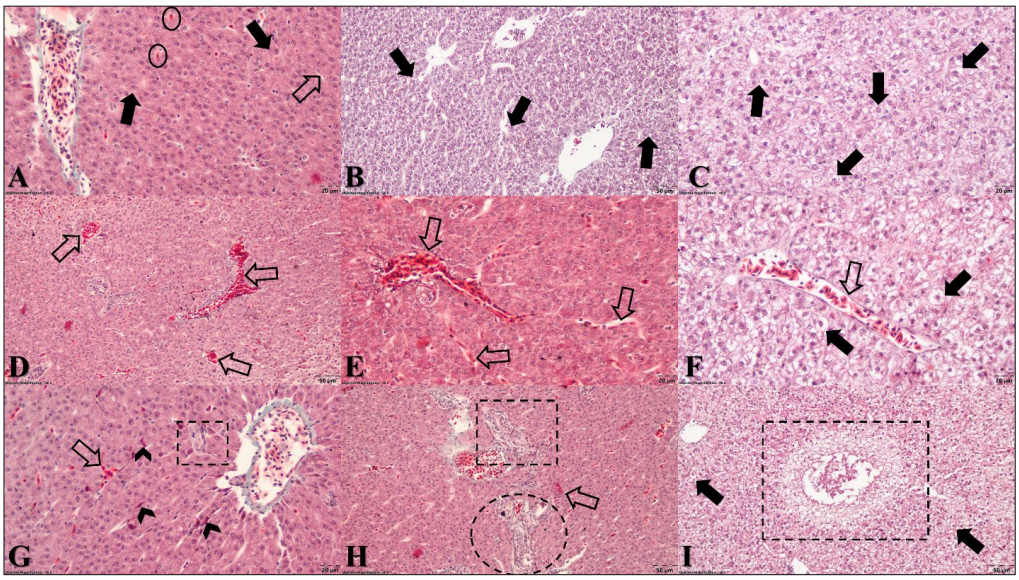


Figure 6. Representative histological sections of liver tissue from chub (*Squalius cephalus*) collected from the negative (A) and positive (B–I) control rivers. (A) Normal hepatic architecture observed in fish from the negative control river; (B–C) Hepatocellular degenerative changes; (D–E) Vascular alterations; (F) Combined hepatocellular and vascular lesions; (G–I) Advanced hepatic lesions, including necrosis and architectural disruption; Black arrows indicate hepatocellular alterations (e.g., vacuolization, degeneration); empty arrows indicate vascular structures and sinusoidal dilation; arrowheads indicate apoptotic cells; dashed rectangles indicate necrotic areas; dashed circles indicate loss of normal hepatic architecture

## DISCUSSIONS

The heavy metal analysis clearly differentiated the two rivers in terms of contamination status. In the positive control river, Mn (1429.4 µg/L) and Fe (7937.7 µg/L) exceeded the thresholds established for Class V (heavily polluted) waters, while the negative control river fell within Class I–II quality, indicating minimal impact. Elevated Fe and Mn concentrations are frequently reported in mining-affected catchments due to metal mobilization from historical ore exploitation (Georgieva et al., 2016; Bănăduc et al., 2021), and similar contamination profiles have been associated with increased bioavailability and toxicity in freshwater ecosystems (Yancheva et al., 2016). Additionally, higher levels of Li, Mg, Al, Co, Ni, Cu, Zn, and As were detected in the polluted river, reflecting a multi-metal exposure scenario typical of mining-derived pollution. Such mixed-metal contamination has been linked to hepatic degenerative and necrotic lesions in fish (Mela et al., 2007; Carrola et al., 2009; Yancheva et al., 2016), supporting the histopathological alterations observed in the present study.

Moreover, the present study demonstrates marked differences in hepatic architecture between European chub (*Squalius cephalus*) collected from a heavy metal-impacted river (positive control) and those from a reference, non-polluted river (negative control). Fish from the contaminated site exhibited a wide spectrum of histopathological alterations, including hydropic and lipid degeneration, vascular hyperemia, apoptosis, necrosis, and disruption of normal parenchymal organization. In contrast, specimens from the reference site displayed preserved hepatic architecture, characterized by polygonal hepatocytes with centrally located spherical nuclei arranged in cord-like structures separated by non-dilated sinusoids containing erythrocytes. These

findings are consistent with the established role of fish liver histopathology as a sensitive biomarker of environmental contamination (Yancheva et al., 2016; Reddy & Rawat, 2013). The normal hepatic morphology observed in fish from the negative control river corresponds to descriptions of healthy teleost liver structure reported in previous studies (Vicenti et al., 2005; Figueiredo-Fernandes et al., 2007; Yancheva et al., 2016). The preservation of hepatocyte polarity, cytoplasmic homogeneity, and sinusoidal organization suggests physiological homeostasis and absence of significant toxicant-induced stress. Such structural integrity is generally indicative of good environmental quality and supports the classification of this river as minimally impacted.

In contrast, the liver alterations recorded in fish from the positive control river reflect a pattern typically associated with chronic exposure to heavy metals and other xenobiotics. Hydropic and lipid degeneration, characterized by cytoplasmic vacuolation and ballooning of hepatocytes, were among the most frequent lesions observed. Similar degenerative changes have been widely reported in fish exposed to metals and organic contaminants (Monteiro et al., 2005; Rajeshkumar & Munuswamy, 2011; Yancheva et al., 2016). Hydropic vacuolation has been linked to ionic imbalance and disruption of membrane-bound ATPases involved in cellular volume regulation (Hinton & Laurén, 1990; Yancheva et al., 2016), while lipid accumulation may reflect metabolic disturbances and impaired lipid processing under toxic stress (Marty et al., 2003; Pinto et al., 2009; Yancheva et al., 2016). The presence of these degenerative patterns in our study strongly suggests sublethal but persistent toxicant exposure in fish inhabiting the positive control river.

Marked vascular alterations, particularly sinusoidal dilation and hyperemia, were also observed in the samples from the positive control river. Increased vascular congestion in the hepatic parenchyma has been described as a common response to environmental stressors and may reflect circulatory disturbances or inflammatory processes triggered by toxic exposure (Yancheva et al., 2016; Reddy & Rawat, 2013). The pronounced sinusoidal dilation observed in our specimens indicates altered hepatic hemodynamics, potentially secondary to endothelial damage or impaired outflow, conditions frequently associated with contaminant-induced hepatotoxicity.

More severe lesions, including a high number of apoptotic hepatocytes and focal areas of necrosis, were identified exclusively in fish from the polluted river. Necrosis is considered one of the most critical histopathological endpoints in toxicological studies and has been repeatedly associated with heavy metal exposure (Mela et al., 2007; Carrola et al., 2009; Yancheva et al., 2016). The occurrence of necrotic foci and parenchymal disorganization in the present study indicates advanced cellular injury and loss of tissue integrity. Such alterations likely result from prolonged oxidative stress, mitochondrial dysfunction, and disruption of cellular homeostasis induced by metal accumulation. Previous investigations in European freshwater systems, including Romanian rivers, have similarly reported correlations between tissue metal burden and hepatic necrosis in chub and other cyprinid species (Triebskorn et al., 2008).

The combination of degenerative, circulatory, and necrotic changes observed in the positive control group reflects a continuum of hepatic injury ranging from reversible cellular alterations to irreversible structural damage. This lesion pattern aligns with the known bioaccumulative and persistent nature of heavy metals in mining-impacted aquatic ecosystems (Georgieva et al., 2016; Bănăduc et al., 2021). Given the documented history of mining activities in the Roșia Montană region (Bănăduc et al., 2021), the hepatic pathology identified in this study likely represents the biological consequence of long-term environmental contamination.

Overall, the clear contrast between the two rivers confirms that hepatic histopathology in *Squalius cephalus* serves as an effective biomarker for assessing ecological impact in metal-polluted freshwater systems. The concordance between our findings and previously published data further strengthens the use of fish liver structural alterations as an integrative indicator of environmental quality (Yancheva et al., 2016; Reddy & Rawat, 2013). These results highlight the importance of

continued biomonitoring efforts in historically impacted mining regions and support the inclusion of histopathological endpoints in comprehensive environmental risk assessment frameworks.

The massive enrichment of trace elements in the substrate compared to the water column at the PCR site indicates a high degree of sedimentary retention. In fluvial systems affected by anthropogenic discharge, heavy metals tend to undergo rapid adsorption onto fine-grained minerals, organic matter, and Fe-Mn oxyhydroxides, leading to their accumulation in the riverbed.

The case of gallium (Ga) and other poorly soluble metals highlights the role of the substrate as a 'long-term memory' of pollution. While the water column reflects the immediate and transient state of the river, the substrate provides a cumulative record of contamination. However, this high sedimentary load poses a latent ecological risk; changes in the river's physico-chemical parameters (such as pH or redox potential) could potentially trigger the remobilization of these sequestered metals back into the water column, increasing their bioavailability and toxicity to the aquatic ecosystem.

The significant prevalence of Se, Ag, In, Sr, Cs, and Tl in the water column at the NCR site suggests that these elements possess high geochemical mobility and low affinity for the local sedimentary matrix. In an anthropogenic context, the fact that these elements are not effectively sequestered by the substrate is concerning; it indicates that they remain in a dissolved or colloidal state, which directly increases their bioavailability and potential toxicity to aquatic organisms.

The high mobility of strontium (Sr) and thallium (Tl) in the aqueous phase of the NCR river suggests a lack of active precipitation or adsorption processes that would typically remove these metals from the water column. These results highlight a critical environmental risk: while other heavy metals might be 'trapped' in the sediment, this specific group remains a persistent threat to the water quality of the NCR system. This high solubility must be considered when evaluating the overall ecological impact of pollution in this river segment.

The lack of statistically significant differences in the water column between the polluted (PCR) and clean (NCR) rivers, despite visual trends, can be attributed to several environmental factors. Metals in the aqueous phase are highly dynamic and subject to rapid fluctuations due to flow rate, pH changes, and dilution effects. The fact that elements like Al, Mn, and Fe showed near-significant increases in PCR suggests a state of chronic low-level enrichment rather than acute contamination in the dissolved phase. It is highly probable that the bulk of the heavy metal load in the polluted PCR system has partitioned into the solid phase. Therefore, the sedimentary substrate likely acts as the primary long-term sink for these pollutants, making the comparison of substrate samples (S-PCR vs. S-NCR) critical for a definitive assessment of the environmental degradation in these two river systems.

The stark contrast between the lack of significant findings in the water phase and the heavy contamination found in the S-PCR substrate highlights the critical role of sediments as the 'environmental memory' of fluvial systems. While dissolved metals are subject to rapid dilution and transport, the substrate acts as a permanent reservoir for contaminants through adsorption and precipitation processes.

The extreme enrichment of aluminium and gallium in the PCR sediments suggests specific industrial or geogenic signatures that are effectively sequestered by the mineral matrix. Furthermore, the high concentrations of manganese and iron are indicative of the formation of Fe-Mn oxyhydroxides, which are known to act as scavenging agents for other trace elements like selenium and cesium indicating a significant ecological risk.

## CONCLUSIONS

The present study demonstrates a clear association between heavy metal contamination and hepatic histopathological alterations in European chub (*Squalius cephalus*). The river impacted by mining-derived pollution exhibited markedly elevated concentrations of Mn, Fe, and several other metals, corresponding to a heavily polluted (Class V) status, whereas the

reference river showed values consistent with good ecological quality. Concordantly, fish collected from the polluted site displayed a broad spectrum of hepatic lesions - including hydropic and lipid degeneration, hyperemia, apoptosis, necrosis, and architectural disorganization - while specimens from the reference site maintained normal liver morphology.

The analysis reveals that the Positive Control River (PCR) exhibits significantly higher heavy metal loads across both water and sediment matrices compared to the Negative Control River (NCR). Sediments in the PCR act as the primary sink for pollutants, showing a marked accumulation of elements like Fe, Al, and Mn that far exceed the levels found in the control site. The widespread statistical significance observed in the sediment-to-sediment comparison confirms a high degree of environmental contamination in the PCR system. Ultimately, these results highlight the role of riverbed sediments as critical indicators for long-term monitoring of heavy metal pollution.

These findings reinforce the value of fish liver histopathology as a sensitive and integrative biomarker for assessing ecological risk in metal-contaminated freshwater ecosystems. The concordance between chemical data and biological responses highlights the ongoing impact of historical mining activities in the study area and underscores the importance of continued biomonitoring and environmental management strategies in affected watersheds.

## ACKNOWLEDGEMENTS

This research was carried out within the project 291/10.03.2025 won by the first author and funded by the Academy of Romanian Scientists.

## REFERENCES

Bănăduc, D., Curtean-Bănăduc, A., Cianfaglione, K., Akeroyd, J. R., & Cioca, L. I. (2021). Proposed environmental risk management elements in a Carpathian valley basin, within the Roşia Montană European historical mining area. *International Journal of Environmental Research and Public Health, 18*(09), 4565.

Bird, G., Brewer, P. A., Macklin, M. G., Serban, M., Balteanu, D., & Driga, B. (2005). Heavy metal contamination in the Arieş river catchment, western Romania: Implications for development of the Roşia Montană gold deposit. *Journal of Geochemical Exploration, 86*(1), 26-48.

Carrola, J., Fontaínhas-Fernandes, A., Matos, P., & Rocha, E. (2009). Liver histopathology in brown trout (*Salmo trutta f. fario*) from the Tinhela River, subjected to mine drainage from the abandoned Jales mine (Portugal). *Bulletin of Environmental Contamination and Toxicology, 83*(1), 35-41.

Dumitrel, G.A., Glevitzky, M., Popa, M., & Vica, M. L. (2015). Studies regarding the heavy metals pollution of streams and rivers in Roşia Montană area, Romania. *Journal of Environmental Protection and Ecology, 16*(3), 850-860.

Figueiredo-Fernandes, A., Ferreira-Cardoso, J. V., Garcia-Santos, S., Monteiro, S. M., Carrola, J., Matos, P., & Fontaínhas-Fernandes, A. (2007). Histopathological changes in liver and gill epithelium of Nile tilapia, *Oreochromis niloticus*, exposed to waterborne copper. *Pesquisa Veterinária Brasileira, 27*(3), 103-109.

Georgieva, E., Yancheva, V., Velcheva, I., Iliev, I., Vasileva, T., Bivolarski, V., Becheva, M., & Stoyanova, S. (2016). Histological and biochemical changes in liver of common carp (*Cyprinus carpio* L.) under metal exposure. *North-Western Journal of Zoology, 12*(2), 261-270.

Glevitzky, M., Bostan, R., Vică, M. L., Dumitrel, G.A., Corcheş, M.T., Popa, M., Glevitzky, I., & Matei, H.V. (2025). Environmental contamination and mining impact: physico-chemical and biological characterization of propolis as an indicator of pollution in the Roşia Montană Area, Romania. *Plants, 14*(6), 866.

Hájková, K., Pulkrabová, J., Hajšlová, J., Randák, T., & Žlábek, V. (2007). Chub (*Leuciscus cephalus*) as a bioindicator of contamination of the Vltava River by synthetic musk fragrances. *Archives of Environmental Contamination and Toxicology, 53*(3), 390-396.

Havelkova, M., Blahova, J., Kroupova, H., Randak, T., Slatinska, I., Leontovycova, D., Grabic, R., Pospisil, R., & Svobodova, Z. (2008). Biomarkers of contaminant exposure in chub (*Leuciscus cephalus* L.) - biomonitoring of major rivers in the Czech Republic. *Sensors, 8*(4), 2589-2603.

Hinton, D. E., & Laurén, D. J. (1990). Liver structural alterations accompanying chronic toxicity in fishes: potential biomarkers of exposure. In: McCarthy J. F., Shugart L. R. (Eds.), *Biomakers of Environmental Contamination.* Boca Raton, USA: Lewis Publishers, 17-57.

Hornung, R. W., & Reed, L. D. (1990). Estimation of average concentration in the presence of nondetectable values. *Applied Occupational and Environmental Hygiene, 5*, 46-51.

Krywult, M., Klich, M., & Szarek-Gwiazda, E. (2008). Metal concentrations in chub, *Leuciscus cephalus*, from a submontane river. *Acta Ichthyologica et Piscatoria, 38*, 47-53.

Lang, T., Wosniok, W., Baršienė, J., Broeg, K., Kopecka, J., & Parkkonen, J. (2006). Liver

histopathology in Baltic flounder (*Platichthys flesus*) as indicator of biological effects of contaminants. *Marine Pollution Bulletin, 53*(8-9), 488-496.

Levei, E., Senila, M., Miclean, M., Abraham, B., Roman, C., Stefanescu, L., & Moldovan, O. T. (2011) Influence of Roșia Poieni and Roșia Montană mining areas on the water quality of the Arieș River. *Environmental Engineering and Management Journal, 10*(1), 23-29.

Marty, G. D., Hoffmann, A., Okihiro, M. S., Hepler, K., & Hanes, D. (2003). Retrospective analysis: bile hydrocarbons and histopathology of demersal rockfish in Prince William Sound, Alaska, after the Exxon Valdez oil spill. *Marine Environmental Research, 56*(5), 569-584.

Mela, M., Randi, M. A. F., Ventur, D. F., Carvalho, C. E. V., Pelletier, E., & Oliveira Ribeiro, C. A. (2007). Effects of dietary methylmercury on liver and kidney histology in the neotropical fish *Hoplias malabaricus*. *Ecotoxicology and Environmental Safety, 68*(3), 426-435.

Ministerul Mediului și Gospodăririi Apelor (MMGA) (Ministry of Environment and Water Management) (2006). Ordin nr.161 din 16 februarie 2006. Ordin al ministrului apelor şi protecţiei mediului pentru aprobarea Normativului privind obiectivele de referinţă pentru clasificarea calităţii apelor de suprafaţă. Monitorul Oficial nr. 511/13 iunie 2006 (Order no. 161 of 16 February 2006. Order of the Minister of Water and Environmental Protection for the approval of the Norm regarding the reference objectives for the classification of surface water quality. Official Gazette no. 511/13 June 2006).

Mireșan, V., Lațiu, C., & Cocan, D. (2016). Age structure and growth dynamics of European chub, *Squalius cephalus*, Linnaeus 1758 (Actinpterygii: Cyprinidae) from two catchments in Transylvania-Romania. *Bulletin UASVM Animal Science and Biotechnologies, 73*(2), 206-211.

Monteiro, S. M., Rocha, E., Fontainhas-Fernandes, A., & Sousa, M. (2008). Quantitative histopathology of *Oreochromis niloticus* gills after copper exposure. *Journal of Fish Biology, 73*(6), 1376-1392.

Pinto, A., Varandas, S., Coimbra, A., Carrola, J., & Fontaínhas-Fernandes, A. (2009). Mullet and gudgeon liver histopathology and macroinvertebrate indexes and metrics upstream and downstream from a wastewater treatment plant (Febros River-Portugal). *Environmental Monitoring and Assessment, 169*, 569-585.

Rajeshkumar, S., & Munuswamy, N. (2011). Impact of metals on histopathology and expression of HSP 70 in different tissues of Milk fish (*Chanos chanos*) of Kaattuppalli Island, South East Coast, India. *Chemosphere, 83*(4), 415-421.

Reddy, P. B., & Rawat, S. S. (2013). Assessment of aquatic pollution using histopathology in fish as a protocol. *International Research Journal of Environment Sciences, 2*(8), 79-82.

Reimann, C., & Filzmoser, P. (2000). Normal and lognormal data distribution in geochemistry: death of a myth. Consequences for the statistical treatment of geochemical and environmental data. *Environmental Geology, 39*, 1001–1014.

Salamat, N., & Zarie, M. (2012). Using of fish pathological alterations to assess aquatic pollution: A review. *World Journal of Fish and Marine Sciences, 4*(3), 223-231.

Stehr, C. M., Johnson, L. L., & Myers, M. S. (1998). Hydropic vacuolation in the liver of three species of fish from the U.S. West Coast: lesion description and risk assessment associated with contaminant exposure. *Diseases of Aquatic Organisms, 32*(2), 119-135.

Stentiford, G. D, Longshaw, M., Lyons, B. P., Jones, G., Green, M., & Feist, S. W. (2003). Histopathological biomarkers in estuarine fish species for the assessment of biological effects of contaminants. *Marine Environmental Research, 55*(2), 137-159.

Suvarna, K. S., Layton, C., & Bancroft, J. D. (2018). *Bancroft's theory and practice of histological techniques*. Amsterddam, NL: Elsevier Publishing House, 584 pp.

Triebskorn, R., Telcean, I., Casper, H., Farkas, A., Sandu, C., Stan, G., Colărescu, O., Dori, T., & Köhler, H. R. (2008). Monitoring pollution in River Mureş, Romania, part II: metal accumulation and histopathology in fish. *Environmental monitoring and assessment, 141*(1), 177-188.

van der Oost, R., Beyer, J., & Vermeulen, N. P. E. (2003). Fish bioaccumulation and biomarkers in environmental risk assessment: A review. *Environmental Toxicology and Pharmacology, 13*(2), 57-149.

Vicenti, C. A., Franceschini-Vicentini, I. B., Bombonato, M. T. S., Bertolucci, B., Lima, S. G., & Santos, A. S. (2005). Morphological study of the liver in the teleost *Oreochromis niloticus*. *International Journal of Morphology, 23*(3), 211-216.

Yancheva, V., Velcheva, I., Stoyanova, S., & Georgieva, E. (2016). Histological biomarkers in fish as a tool in ecological risk assessment and monitoring programs: a review. *Applied Ecology and Environmental Research, 14*(1), 47-75.