

## THE UMBILICAL RING OF RUMINANTS, NATURAL GATE FOR TRANSPONDER IMPLANT INTO THE PREPERITONEAL SPACE

Sorin LUNGU, Anca LUNGU, Horia GROSU

University of Agronomic Sciences and Veterinary Medicine of Bucharest, Animal Science Faculty,  
U.A.S.V.M. Bucharest, 59 Mărăști Blvd, District 1, 011464, Bucharest, Romania

Corresponding author email: lunguso@gmail.com

### **Abstract**

*The ruminant identification is an important tool aimed to establish safely animal ownership, for animal health monitoring and control, food safety control, and finally for genetic selection.*

*For ruminants the technologies developed during the last years do not allow to ensure that a certain set of basic requirements are met: absence of migration of transponder, fast recovery of transponder in slaughterhouse, possible application in the second part of the meat cutting chain. Therefore, a safe and reliable identification system is needed to ensure live animals and products traceability throughout the food production chain. Implanting of an electronic device into the preperitoneal space by patent of umbilical cord and ring, for performing electronic identification of ruminants may represent a positive answer for the above requirements.*

*This procedure relates to an electronic system for identification and monitoring of small and big ruminant animals, from birth until cutting and utilization of meat cuts.*

*Experiments were carried out in experimental farm conditions of National Research Development Institute for Animal Biology and Nutrition. Our preliminary investigations about methodology, were made with the intent, to explore if is possible to be used, in real farm conditions.*

**Key words:** *Animal individualization, transponder, umbilical cord, umbilical ring.*

### **INTRODUCTION**

The ruminant identification is an important tool aimed to safely establish animal ownership, for animal health monitoring and control, food safety control, and finally for genetic selection. Therefore, a safe and reliable identification system is needed to ensure live animals and products traceability throughout the food production chain.

According to recent EU Council Directives, concerning identification and registration of small and big ruminants, must be marked as soon as possible with double identification: an ear-tag and as second tag, an electronic device. Frequently as second electronic tag, is used the ruminal bolus. Is a transponder housed in a specific gravity container (e.g. ceramic) which is orally administered to a ruminant and that remains (due to its weight, shape and size) permanently in the reticulo-rumen (forestomach). Because the electronic device is deposited in reticulum, there is some limitation to the minimum age - 3 weeks and older - at which a bolus can be introduced. The

application of boluses requires appropriate training.

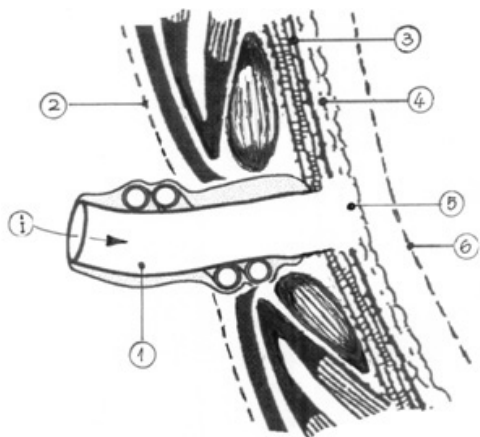
On this background of good results, but in the same time, sufficient space for new solutions, we have had idea to use what the nature gave us, namely the temporal opening of umbilical ring, as a good passageway for implanting of an electronic device into the preperitoneal space.

### **MATERIALS AND METHODS**

Animal test group. The study involved a sample size of 54 newborn animals (lambs and calves), in experimental farm of National Research Development Institute for Animal Biology and Nutrition. Technical and clinical investigations concerning the present breeding process were carried out. In particular, the preliminary investigations concerned the husbandry environment during the farrowing phase (cleaning and disinfection procedure, ventilation system) and animal condition (vaccination, health condition).

Electronic identifiers. A cylindrical, glass encapsulated transponder, has been used to identified electronically the newborns.

Brief Description of the Implantation Technique. The implant procedure has been designed for ruminants. The neonate should be restraining in dorsal recumbent position, in a resistless position; only in this position the muscles of abdominal wall will pass into relax, offering no resistance.



- I. Direction of transponder implantant;
1. Umbilical cord;
  2. Skin plus fatty layers;
  3. Transversalis fascia posterior lamina;
  4. Preperitoneal fat and space of Bogros;
  5. Properitoneal space, appropriate for transponder's implant by patent of umbilical cord;
  6. Parietal peritoneum.

The first steps of cleansing the umbilical stump, and holding the umbilicus upright, it are followed by the introduction the tip of the transponder into the lumen as deeply as possible; once the transponder is in good position into the cord, continue to advance with gentle motion; when the tip of transponder is arrived at the umbilical ring level, a normal resistance is encountered. After this moment it is sufficient, to bent at 50 - 60 degree and by a simple gentle pushing toward to xiphoid, midline direction, to implant the transponder into properitoneal tissue (Figure 1). By palpation, it is possible to fell, the size, firmness, location of transponder.

## RESULTS AND DISCUSSIONS

In contrast to the vital role played by the umbilicus in utero, it has minimal physiologic importance after birth. Umbilical ring is a natural defect, an opening in the abdominal wall through which the umbilical cord passes and meets the fetus. Shortly after birth, the opening in the abdominal wall, begin to close.

These two aspects, the presence of a flexible cord and temporary opening of umbilical ring, are key elements in our methodology used for individualization of ruminants.

The flexibility of umbilical cord plus the presence of Wharton's Jelly lead the electronic device in direction of umbilical ring, and opening of umbilical ring, the implant the transponder in region of preperitoneal. Preperitoneal (properitoneal) space there is between the peritoneum and posterior lamina of the transversalis fascia.

Because, shortly after birth, the reduction in temperature starts a physiological process which causes the Wharton's Jelly from umbilical cord to swell, the implant of transponder is made early, in the first 1-15 postnatal hours, also due to concern about the closure of the umbilical ring. Functional closure of the umbilical ring usually occurs within minutes of birth and structural closure occurs within three to seven days of birth in term neonates.

Due the fact that the tendinous aponeurotic fibers what surround the umbilical ring, evolve the closing process, in a way similar to the shutter mechanism used in optical instruments, process that occurs, from the inside out, the implant of transponder, stops at level of transverse fascia. Therefore we have had use this properitoneal space, as a suitable, appropriate place for transponder's implant, by patent of umbilical cord (Figure 2).

The readability of the transponders before and after the implant was verified using a portable reader. With the second reading performed after the tagging as 'control reading' to verify the transponder readability, was possible to issue the 'previous list' (i.e. the list of tagged lambs expected to be read during the following control readings). The comparison between reading sessions performed at predefined dates allowed to record the retention

rate as well as the proper functioning of transponders.

Up to the date of this communication, was not possible the slaughtering of an animal from experimental lot, for assess if in total, the set of basic requirements are met: absence of migration of transponder, fast recovery of transponders in slaughterhouse, possible application in the second part of the meat cutting chain.

But, according to our latest experiments, in normal conditions, the reaction of the host connective fibrous fascia provides a good encapsulation for the transponder. That because deep implanted transponder behaves like any common inert foreign objects, causing a benign reaction in host tissues. Capsule formation around the transponders is able to maintain them in situ.

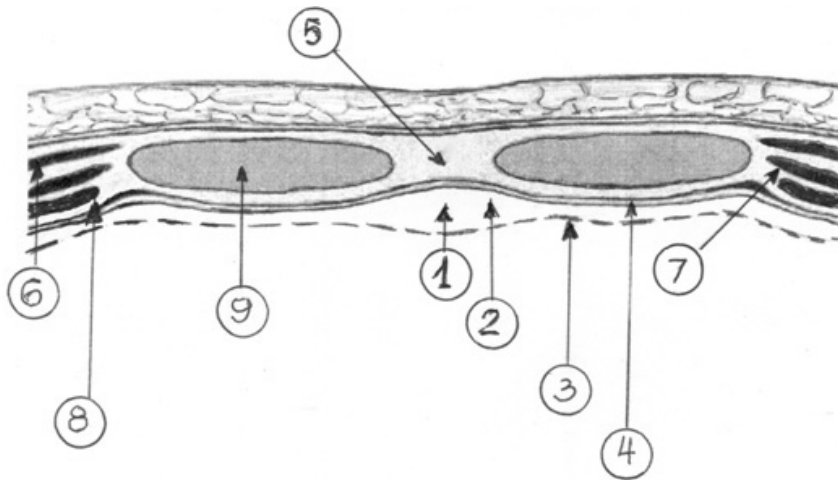


Figure 1. Representation of the layers of the abdominal wall and the properitoneal zone of the implant

1. Properitoneal space, appropriate for transponder's implant by patent of umbilical cord;
2. Properitoneal fat (tela subserosa);
3. Parietal peritoneum;
4. Transversalis fascia;
5. Linea alba;
6. External oblique muscle;
7. Internal oblique muscle;
8. Transversus abdominis muscle;
9. Rectus abdominis muscle

The fact that more than ten reading sessions had been performed with success, it is a clear confirmation of presence of the electronic device in respectively area.

But, according to our latest experiments, in normal conditions, the reaction of the host connective fibrous fascia provides a good encapsulation for the transponder. That because

deep implanted transponder behaves like any common inert foreign objects, causing a benign reaction in host tissues. Capsule formation around the transponders is able to maintain them in situ. The fact that more than ten reading sessions had been performed with success, it is a clear confirmation of presence of the electronic device in respectively area.

For moment, in base of this aspect we can only suppose that, the electronic device can be easy localized in the umbilical zone of carcasses, supposition what follow to be clarified by slaughtering of some animals from experimental lot.

According to our knowledge, the application of a transponder in the properitoneal zone, by patent of umbilical cord has never been explored.

## CONCLUSIONS

This methodology may represent a positive answer to the above requirements and can also ensure an easy and efficient mean to trace-back the animal(s) and the product(s) to the farm of origin (due to the fact that the animal will be individually identified). In addition, it allows keeping the ruminant identification throughout the slaughtering process (where it could play the role of carcass identification) and the meat cutting process.

## REFERENCES

- Askar, O.M. et al., 1993. The umbilical ring, *Surgical Clinics of North America*, 64, p. 315-333.
- Brewer, S., Williams, T., 2004. Finally, a sense of closure? Animal models of human ventral body wall defects, *Biology Essay*, 26, 12, p. 1307-1321.
- Buthler, H., 2009. Post-natal changes in the intra-abdominal umbilical vein, *Archives of Disease in Childhood*, 1854, p. 427-435.
- Desmoulièr A., Chaponnier Ch., Gabbiani G., 2006. The evolution of the concept of Myofibroblast: implication for normal and pathological tissue remodeling, In: Chaponnier et al.- *Tissue repair, Contraction and the Myofibroblast*. Swiss National Science Foundation, Geneva, Springer and Landers Biosciences.
- Lungu A., B. Georgescu, S. Lungu, 2009, Evolutional morphology of the umbilical cord in the perinatal life time in calves. *Lucrări Stiințifice Medicină Veterinară* vol. XLII (2), Timisoara
- Mirilas P., MD, MSurg, Gene L. Colborn, David A. McClusky, Lee J. Skandalakis, Panajiotis N. Skandalakis, John E. Skandalakis, 2005. The History of Anatomy and Surgery of the Preperitoneal Space. *Arch Surg.*; 140(1): p. 90-94. doi:10.1001/archsurg.140.1.90.